

Utility of flash visual evoked potentials in infants and children with delayed milestones

Kothari Ruchi¹, Singh Smita², Jain Manish³, Bokariya Pradeep⁴, Singh Ramji¹

¹Department of Physiology, Mahatma Gandhi Institute of Medical Sciences, Sevagram, India

²Department of Ophthalmology, Mahatma Gandhi Institute of Medical Sciences, Sevagram, India

³Department of Pediatrics, Mahatma Gandhi Institute of Medical Sciences, Sevagram, India

⁴Department of Anatomy, Mahatma Gandhi Institute of Medical Sciences, Sevagram, India

Abstract

Visual Evoked Potential (VEP) is a non-invasive technique used to assess the integrity and relative state of maturation of the visual pathways in infants and children. Flash VEPs were recorded using Evoked Potential Recorder (RMS EMG. EP MARK II) with a red flash stimulus obtained from LED (Light Emitting Diode) Goggles. The present study was conducted in the Neurophysiology department on infants and children who presented with developmental delay. A total of 40 infants and children in the age group of 9 months to 10 years participated as subjects and 65 healthy age matched infants as controls were included in the study. The data of VEP recordings was analyzed for the latency and amplitude of the first reproducible positive peak for both eyes separately. The mean and standard deviations were computed for all recordings and statistical significance was derived from unpaired student's "t" test. There was statistically significant difference in latency and amplitude of VEPs obtained from normal infants and children & those with delayed milestones. Abnormal flash VEP findings as compared to the normative data suggest abnormal visual function in the infants and children who showed significantly delayed developmental milestones.

Key words: Visual evoked potential, LED goggles, developmental delay

Accepted April 04 2010

Introduction

Visual evoked potentials (VEPs) have become an indispensable tool in pediatric ophthalmology and neurology and have been known to provide prognostic information in several pediatric visual disorders. The clinical value of VEP testing does not lie in the detection or differential diagnosis of pediatric diseases. Instead, the strength of VEP assessment lies in the quantitative measurement that it provides of the degree of visual impairment [1]. A group of infants and children who fail to show normal visual maturation of visual function in infancy without having any apparent ocular abnormality are classified under Delayed visual maturation (DVM) [2]. In all forms of DVM, infants behave as visually impaired and visual impairment can significantly impair normal development. Thus delay in developmental milestones when accompanied with DVM presents as a diagnostic dilemma to a neurophysiologist. An incorrect diagnosis of visual impairment in an infant whose milestones are delayed can be detrimental to his family.

In this context, this article discusses the evaluation of visual system of patients with delayed milestones using visual evoked potential (VEP) and an attempt has been made by us to explore the ability of VEP recordings to demonstrate the neurophysiologic basis for pediatric visual impairment in cases of delayed development.

Material and Methods

The present study was conducted in the Neurophysiology Unit of Dept. of Physiology, MGIMS Sevagram. The subjects included infants and children who were referred from the Pediatric department of Kasturba Hospital when they were identified as having delayed developmental milestones during their screening examination. A total of 40 infants and children between the ages of 9 months to 10 years constituted the patient group. Sixty five healthy infants as age matched controls were included in the study. This project was approved by the hospital's ethics committee and written parental consent was obtained.

Inclusion criteria were delayed developmental milestones as assessed by the pediatrician using Denver Development Screening Test (DDST). According to this test the child's development is categorized under four heads- gross motor, fine motor, personal, social and language functions.

All subjects had ocular screening examination and showed no anterior segment abnormality in the eye, had normal pupillary reflexes, followed light and had clear ocular media with normal fundus by direct ophthalmoscopy. Children with obvious discernible cause of visual dysfunction on examination such as cataract, glaucoma, corneal scars and retinal detachment were excluded. A comprehensive history was taken and flash VEP was performed on each patient.

The recording was done in a quiet dark room where constant temperature (27-30°C) was maintained throughout. The stimulus was a red flash delivered by the light emitting diode (LED) goggles. The equipment used was compact and the technique simple, causing minimal disturbance to the infants. The LED goggles were held in front of the infant's eyes, against the forehead and cheeks, in such a way that little or no extraneous light was admitted during the testing.

Standard disc EEG electrodes were placed on the scalp areas after preparing the skin by degreasing and abrading with a conducting jelly or electrode paste (RMS recording paste) rubbed lightly into the area with a cotton swab. The standardized methodology as recommended by the International Federation of Clinical Neurophysiology (IFCN) Committee and International Society for Clinical Electrophysiology of Vision (ISCEV) was followed. As per 10-20 International System of EEG placements, the reference electrode (Fz) was placed in the mid-frontal area and the ground electrode (Cz) at the vertex and the active electrode (Oz) at approximately 2 cm above theinionode impedance was kept below 5KΩ.

Two or more averages of 30- 60 trials were recorded to artifacts were rejected with the help of an artifact reject circuit which also eliminated epochs that were contaminated by head and body movement. VEP latency and amplitude were evaluated to the prominent reproducible positive wave P2 wave. A major peak or trough was defined as the largest amplitude peak or trough within a 130 ms segment of that trial, i.e. no larger excursions appeared from baseline within ± 65 ms.

Statistical analysis

The data of VEP recordings was analyzed for the latency and amplitude of the first reproducible positive peak for both eyes separately. The mean and standard deviations were computed for all recordings and statistical significance was derived from unpaired student's "t" test.

Results

The values of VEP parameters of the subjects with delayed milestones are tabulated in Table 1. The mean age at presentation was 6.05 ± 3.53 years for the patients and 6.24 ± 2.62 years for the control group. The VEP parameters obtained for the patient group were outside 2SD of the mean normal values of the controls

The mean VEP amplitude of the patient group was recorded as 5.89 ± 3.20 μ V for right eye and 5.47 ± 3.23 μ V for left eye. In the control group the VEP amplitude was 12.24 ± 3.57 μ V for the right eye and it was 12.18 ± 3.59 μ V for the left eye. This difference of means was statistically significant ($P < 0.001$) for both eyes.

The overall mean ± 1 SD value of P2 latency for right eye in the patient group was 107.26 ± 7.38 msec. and for the control group, it was 97.19 ± 5.60 msec. Similarly the mean values in left eyes of P2 latency for the patient group was 106.38 ± 7.29 msec. and that for controls was 97.44 ± 3.57 msec respectively. This difference between cases and controls was also statistically significant.

Table 1: Mean VEP Latencies and Amplitudes

	Age	RE P2 Latency msec	LE P2 Latency Msec	RE P2 Amplitude μ V	LE P2 Amplitude μ V
Patients (mean \pm SD) n = 40	6.05 ± 3.53	107.26 ± 7.38	106.38 ± 7.29	5.89 ± 3.20	5.47 ± 3.23
Controls (mean \pm SD) n = 65	6.24 ± 2.62	97.19 ± 5.60	97.44 ± 3.57	12.24 ± 3.59	12.18 ± 3.59
P Value	$P > 0.05$	$P < 0.05$	$P < 0.05$	$P < 0.001$	$P < 0.001$

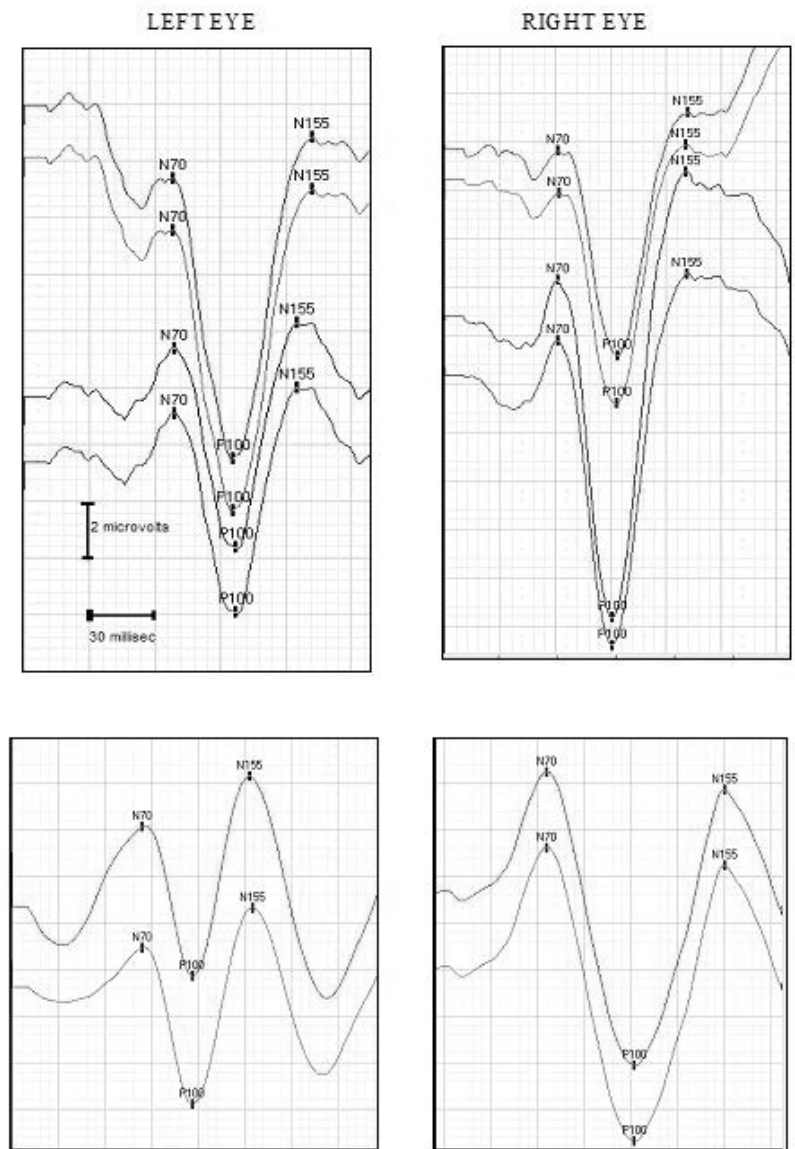


Figure 1. VEP Waveform Morphology
 VEP Record of a child of 4 years with developmental delay (Lower Panel)
 VEP Record of a child of 4 years in the control group (Upper Panel)

The latency of first prominent wave of visually evoked potentials was mildly prolonged in a female subject of 4 years. She had exotropia in the right eye which might have resulted in monocular prolongation of latency. Another male child of 10 years had markedly prolonged latencies in both eyes as compared to the control data. The probable cause could be the presence of autism which was an additional diagnosis to global developmental delay. “W” Pattern or bifid P wave morphology was observed in 8 (20%) patients who had gross and fine motor delays along with delay of social smile and language functions. Abnormally delayed latency and missing components of the waveform were obtained in VEP records of 5 (12.5%) patients who were diagnosed as having global develop-

mental delay along with bilateral primary optic atrophy. Markedly reduced amplitude of P wave was a common finding in 18 (45%) patients with a diagnosis of Microcephaly, delayed milestones with mental retardation. Unusual and improper waveform was obtained in 7 (17.5%) patients with developmental delay associated with febrile convulsion.

Discussion

Our study attempts to evaluate and assess the VEP findings in children diagnosed as having delayed developmental milestones accompanied with delayed visual maturation. Delayed visual maturation (DVM) is an idio-

pathic condition which may be one of the several manifestations of global development delay in children.

Several studies have shown that children with DVM are frequently delayed in other spheres of development also. Hoyt [3] noted general delays in motor development of 7 to 8 children with DVM and all of them had VEPs with decreased amplitudes or delayed latencies. Our study has also demonstrated significant correlation of VEP with moderate to severe developmental delay.

Cole [4] reported that several children with DVM were slow in learning to speak. 2 of 16 cases in his series developed epilepsy and one in 9 in the series by Lambert [5] had a seizure disorder. Seizures can affect general alertness including visual behavior [6] and can be considered as a factor responsible for unusual and improper waveform obtained in 7 cases of the patient of our study.

Flash VEPs have been reported to be abnormal in most infants with DVM by Kraemer [7], which is in agreement with our findings. The abnormalities described include delay of the major positivity, decreased amplitudes and immature waveforms.

Mellor and Fielder [8] reported that flash VEPs were delayed or absent in 4 children with DVM (delayed visual maturation). Harel [9] described 3 infants with DVM who had Flash VEPs with delayed latencies normalized by 1 year of age. Fielder [10] reported a large series of children with DVM in which 78% had flash VEPs with prolonged latencies, abnormal waveform and decreased amplitudes.

It has been documented in the past that microcephaly leads to more than 40% reduction in VEP amplitude. The small head size might be a possible cause of reduced VEP amplitudes found in microcephalic children of the present study.

The abnormal flash VEP findings of our study in cases of developmental delay with DVM are in consonance with most of the previously reported studies which have described abnormal or absent visual evoked responses in such infants.

The evidence of abnormal VEP record with respect to delayed latencies and reduced amplitude in infants and children with delayed milestones indicates the possibility of immaturity of macula, delay in foveal development or delay in myelination of visual pathways as the prime contributory factors along with delayed dendritic formation and synaptic development in the occipital cortex. Yet the exact etiology behind this phenomenon still needs to be unleashed.

Conclusion

In this study, flash VEPs were recorded using LED goggles in the controls and the patient group. VEPs obtained

in the patient group of our study include the abnormalities like delay of the major positivity, decreased amplitudes and immature waveforms and these abnormal flash VEP findings as compared to the normative data suggests abnormal visual function in the infants and children who showed significantly delayed developmental milestones of infancy and childhood.

References

1. Birch EE, Bosworth RG. Visual Evoked Potentials in Infants and Children: In: Aminoff M.J. (Ed.) *Electrodiagnosis in Clinical Neurology*, 5th ed. New York: Churchill -Livingstone, 2004; pp 439-450.
2. Duckman RH. Delayed Visual Maturation. *Journal of Behavioral Optometry* 2008; 19 (5):115-118
3. Hoyt CS, Jastrzebski G, Marg E. Delayed Visual Maturation in Infancy. *Br J Ophthal* 1983; 67 :127-130
4. Cole GF, Hungerford J, Jones RB. Delayed visual maturation. *Arch Dis Child* 1984; 59: 107-110
5. Lambert SR, Kriss A, Taylor D. Delayed visual maturation. A longitudinal clinical study and electrophysiological assessment. *Ophthalmology* 1989; 98: 524-529.
6. Russell-Eggitt I, Harris CM, Kriss A. Delayed visual maturation: an update. *Dev Med Child Neurol* 1998; 40:130-136.
7. Kraemer M, Abrahamsson M, Sjöström A. The neonatal development of the light flash visual evoked potential. *Doc Ophthalmol* 1999; 99: 21-39.
8. Mellor DH, Fielder AR. Dissociated visual development: electrodiagnostic studies in infants who are 'slow to see'. *Dev Med Child Neurol* 1980; 22: 327-35.
9. Harel S, Holtzman M, Fiensod M. Delayed visual maturation. *Arch Dis Child* 1983; 58 : 298-309
10. Fielder AR, Russell-Eggitt IR, Dodd KL, Mellor DH. Delayed visual maturation. *Trans Ophthalmol Soc UK* 1985; 104: 653-661.

Correspondence:

Ramji Singh
Department of Physiology
Mahatma Gandhi Institute of Medical Sciences
Sevagram, India
E-mail: sramji57@gmail.com
Mobile: +919423421794

