

Wilson's disease with Heterotaxy syndrome: A Case Report

Sriram P, Shanmuga Arumugaswamy, Nivedita Mondal, Bharat Chaudary, Arun G.K.

Department of Pediatrics, JIPMER, Puducherry, India

Abstract

Wilson's disease (hepatolenticular degeneration) is a rare, treatable, autosomal disorder of copper metabolism leading to liver and brain damage. Its incidence is 1/500,000-1/100,000 live births with more than 250 different mutations [1]. However its association with Heterotaxy syndrome in the form of situs inversus totalis has not been reported till date in Indian literature. We report such a case admitted to our hospital.

Key words: Situs inversus totalis, Heterotaxy, Wilson's disease.

Accepted April 09 2010

Introduction

Wilson's disease (hepatolenticular degeneration) is an autosomal recessive disorder characterized by chronic liver disorder, degenerative changes in the brain and KF rings in the cornea. Its unusual modes of presentation include renal fanconi syndrome, hypoparathyroidism, chronic arthritis, coombs negative hemolytic anemia and cardiomyopathy [2]. However its association with Heterotaxy syndrome in the form of situs inversus totalis has not been reported till date.

Case report

A twelve year old female child was admitted in our hospital with speech difficulty, abnormal posturing of limbs, intentional tremor with history of laughing episodes and emotional disturbances for a period of two months. There was no history of consanguineous marriage among the parents. The child's developmental history was normal for age. The child was conscious with normal vitals with normal developmental milestones. Child was normotensive with dextrocardia and liver palpable on the left side. Neurological examination revealed a conscious child with good retention and recall. There was speech difficulty in form of dysarthria with low word outflow with good comprehension, naming and vocabulary. There was intention tremor with dystonia. There was abnormal behavior with inappropriate laughter. Ophthalmological examination showed KF ring. The sensory examination was normal with no signs of cerebellar dysfunction.

Investigations revealed hemoglobin of 13gm%, total leukocyte count 8300mm³ with 60% Neutrophils, 6% Eosinophils and, 34% lymphocytes. Blood sugar was 125mg/dl, total protein 6.8 g/dl, serum albumin 3.7g/dl,

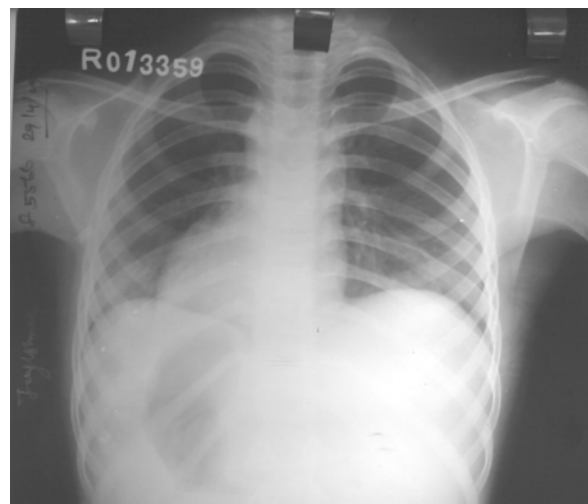


Figure 1. *Situs inversus totalis*

with serum sodium 138 meq/L, potassium 4.6meq/L, total serum bilirubin was 0.6mg/dl, AST 39IU, ALT 27IU, ALP 221 IU with GGT 26 IU. Serum ceruloplasmin was 10mg/dl with 24 hr urinary copper of 400mcg/dl. USG Abdomen showed left sided hydronephrosis, however renal function tests were normal. Chest x ray showed situs inversus with cardiac apex and left atrium and the stomach bubble to the right and liver on the left side [Fig 1]. ECG showed P axis of 120 degrees and Q waves in V1, V2, V5R and V6R. ECHO study showed Dextrocardia with D- loop with ventricular inversion.

Child was confirmed to be Wilson's disease with neuropsychiatric manifestation in the form of dystonia, dysarthria with abnormal behavior and inappropriate laughter. The child was put on Zinc acetate and was advised regular follow up. Child was readmitted three months later with severe neuropsychiatric manifestations.

The child developed Jaundice, generalized anasarca with features of hepatocellular failure and expired due to hepatic encephalopathy and hepatorenal syndrome. Investigations revealed hemoglobin of 7.8gm%, total leukocyte count 13300mm³, neutrophil 64%, eosinophil 04%, lymphocyte 32%. Blood urea was 92mg/dl, serum creatinine 4.2mg/dl, Blood sugar 120mg/dl, total protein 4.8gm/dl, serum albumin 2.7gm/dl, serum sodium 128meq/L, potassium 3.6meq/L, total serum bilirubin of 12.6mg/dl, AST 49IU, ALT 37IU, ALP 261 IU with prothrombin time of 40secs. Post mortem liver biopsy showed macronodular cirrhosis with kupffer cells hyperplasia with extensive periportal fibrotic changes.

Discussion

Wilson's disease (hepatolenticular degeneration) is an autosomal recessive disorder characterized by chronic liver disorder, degenerative changes in the brain and Kayser- Fleischer rings in the cornea [3]. It is worldwide in distribution but more common in Jews, Arabs, Italians, Japanese, Chinese, Indian and any community having higher intermarriage rate [4]. The abnormal gene for Wilson's disease is localized to the long arm of chromosome 13 (13q 14.3). The Wilson disease gene encodes a copper transporting P-type ATPase, ATP 7B [5]. Absence or malfunctioning of ATP 7B results in decreased biliary copper excretion and diffuse accumulation of copper in the cytosol of hepatocytes. There are about 250 mutations which can account for the various modes of presentation. H1069Q mutation was the most common mutation found in 50-80% of cases. The variability predicts the age of onset as well as predicts the course of illness in Wilson's disease which is otherwise is a progressive and fatal if untreated. The mutation that completely knocks out the gene function are associated with onset of the disease as early as 2-3years of age when Wilson's disease may not be typically seen. This variability in context of the children with heterotaxy syndromes in the form of situs inversus totalis has not been described as yet. The cloning of the gene in Wilson's disease raises the prospect of precise presymptomatic detection of Wilson disease, timely initiation of therapy and ultimately the gene therapy. The treatment modalities available are D- Pencillamine, Triethylene tetramine dihydrochloride, Ammonium tetra thio molybdate, Zinc acetate and pyridoxine.

Heterotaxy syndromes may be in the form of asplenia or polysplenia syndromes or with situs inversus totalis with isomerism of viscera, atria, ventricles or the great vessels or all the three. Asplenia syndrome is in the form of Right sided isomerism, centrally located liver, absent spleen with two morphologically Right lungs with complex congenital heart disease [7]. Polysplenia syndrome is in the form of small multiple spleens, absence of intra-

hepatic portion of inferior venacava and bilateral left lungs [8].

In our case the child presented with speech difficulty, abnormal posturing of limbs, intentional tremor with history of laughing episodes and emotional disturbance for a period of two months. There was a Viscero atrial sinus inversus with right sided heart and apex. A diagnosis of Wilson's disease with Heterotaxy syndrome was made. Since the child presented with neuropsychiatric symptoms, zinc therapy was preferred over pencillamine as latter would enhance neurotoxicity at the early phase of treatment. Zinc therapy has been used as adjuvant therapy, maintenance therapy and in presymptomatic patients owing to its unique ability to impair gastrointestinal absorption of copper. [9] However the child had rapid and downhill progression and developed hepatocellular failure.

The screening of the family members, early diagnosis and treatment at the presymptomatic stage with regular clinical and biochemical follow up would improve the clinical outcome in Wilson's disease especially in context of complex presentation with heterotaxy syndrome.

References

1. Ala A, Walker AP, Ashkan K, Dooley JS, Schilsky ML. Wilson disease. *Lancet* 2007; 369: 397-408.
2. Taly AB, Meenakshi-Sundaram S, Sinha S, Swamy HS, Arunodaya GR. Wilson disease. Description of 282 patients evaluated over 3 decades. *Medicine* 2007; 82:112-121.
3. Loudinos G, Gitilin JD. Wilson's disease. *Semin Liver Dis* 2000; 20: 353-364.
4. Schilsky ML. Wilson disease: New insights into pathogenesis, diagnosis and future therapy. *Curr Gastroenterol Rep* 2005; 7: 26-31.
5. Tao TY, Gitilin JD. Hepatic copper metabolism: Insights from genetic disease. *Hepatology* 2003; 37: 1241-1247.
6. Brewer GJ, Hedera P, Kluin KJ, Carlson M, Askari F, Dick RB et al: Treatment of Wilson's disease with ammonium tetrathiomolybdate. *Arch Neurol* 2003; 60: 379-85.
7. Britz- Cunningham SH, Shah MM, Zuppan CW, Fletcher WH. Mutation of the connexin 43 gap-junction gene in patients with heart malformations and defects of laterality. *N Engl J Med* 1995; 332: 1323-1329.
8. Rose V, Izukawa T, Moes CAF. Syndromes of asplenia and polysplenia: A review of cardiac and non-cardiac malformations in 60 cases with special reference to diagnosis and prognosis. *Br Heart J* 1975; 37: 840-852.
9. Brewer GJ, Dick RD, Johnson VD, Brunberg JA, Kluin KJ, Fink JK. The treatment of Wilson's disease with zinc: XV. Long-term follow-up studies. *J Lab Clin Med* 1998; 132:264-278.

Wilson's disease with Heterotaxy syndrome