

## **Paramyotonia congenita with mutation at SCN4A gene**

**Rajesh K Kulkarni, Ashok D Rathod**

Department of Paediatrics, Grant Medical College and Sir JJ Hospital, Byculla, Mumbai 400008, India

### **Abstract**

**Paramyotonia Congenita is a rare neuromuscular disorder characterized by paradoxical myotonia. Nine persons affected in a family over three generations are reported. The proband, who had the most severe symptoms, responded well to acetazolamide. This is the first report of kindred with paramyotonia congenita with proven Arg 1448 Cys mutation at SCN4A gene from India.**

**Keywords:** Paramyotonia, Exacerbation by cold, Acetazolamide, Arg 1448 Cys mutation at SCN4A gene.

*Accepted June 4 2009*

### **Introduction**

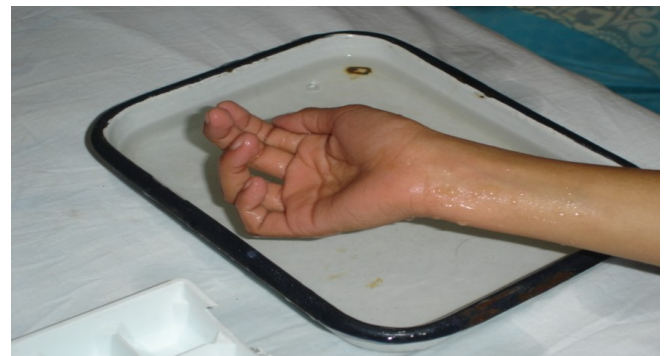Paramyotonia congenita, a non dystrophic type of myotonia is a rare hereditary muscle disorder classified under ion channel diseases or channelopathies. It is inherited as an autosomal dominant disease of sodium channel. The weakness may be diffuse as in hyperkalemic periodic paralyses or limited to the part of the body that is cooled. Weakness may persist for several hours even after the body is rewarmed. Here we report nine members of a family affected with this condition that were investigated and found to have Arg 1448 Cys mutation at SCN4A gene.

### **Case Report**

The proband was a 10 year old girl, born of non consanguineous marriage who presented with difficulty in standing up from sitting position and initiating walking after sitting for some time. Patient also had difficulty in opening eyes in the morning. These symptoms worsened during cold weather and if the child did not eat food for more than few hours. These symptoms were noticed since early infancy but had worsened over time. The child was unable to open eyes once she had tightly shut them voluntarily. Release of the hand grip was very slow and was more prolonged on dipping the patient's hand in cold water (Fig 1)

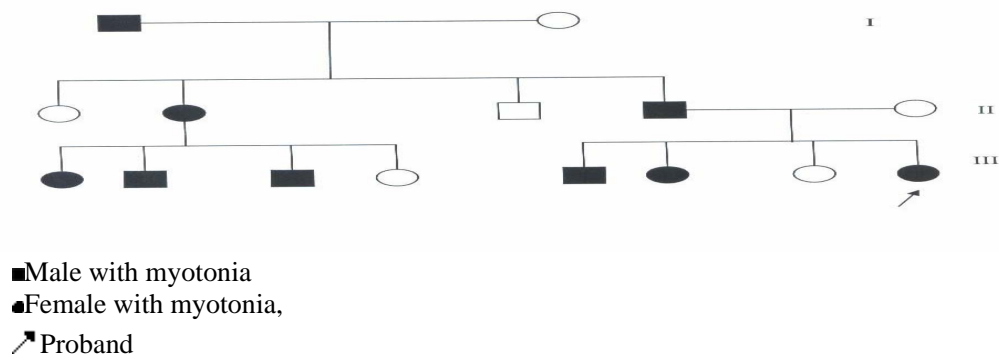
The child had Congenital Talipes Equinovarus (CTEV) of the left foot which was operated at the age of 14 months. The postoperative course was uneventful. The developmental milestones were achieved at an appropriate age.

Detailed family history and pedigree charting revealed eight other persons in the family, including the father, were affected in an autosomal dominant inheritance pattern (fig 2). The youngest patient was 8 year old while the oldest was 65 year old. The other patients had less severe symptoms as compared to the proband. Patient's serum electrolytes were normal. Electromyography (EMG) revealed evidence of primary myotonic discharge consistent with the diagnosis of paramyotonia. Muscle biopsy was normal.



**Fig. 1:** Difficulty in opening hand on immersing in cold water

Molecular biological study revealed a common missense mutation (Arg1448Cys) at the voltage-gated sodium channel gene (SCN4A) in all affected patients. The proband was started on acetazolamide and a good response was noted. The child had no difficulty in opening eyes and was able to release the hand grip easily. The child continues to be on acetazolamide and no undesirable adverse effects have been noted till date.



**Figure 2:** Pedigree chart showing autosomal dominant inheritance pattern affecting three generations

## Discussion

Paramyotonia Congenita (PC), or Eulenburg disease [1], is a rare congenital autosomal dominant neuromuscular disorder characterized by “paradoxical” myotonia. This type of myotonia has been termed paradoxical because it becomes worse with exercise whereas classical myotonia, as seen in myotonia congenita, is alleviated by exercise. PC is also distinguished as it can be induced by cold temperatures. PC typically presents within the first decade of life and has 100% penetrance. Patients with this disorder commonly present with myotonia in the face or upper extremities. The lower extremities are generally less affected. This disease can also present as hyperkalemic periodic paralysis and there is debate as to whether the two disorders are actually distinct [2].

Patients typically complain of muscle stiffness that can continue to focal weakness. This muscle stiffness cannot be walked-off, in contrast to myotonia congenita. These symptoms are increased (and sometimes induced) in cold environments. For example, some patients have reported that eating ice cream leads to a stiffening of the throat. For other patients, exercise consistently induces symptoms of myotonia and/or weakness. Typical presentations of this are during squatting or repetitive fist clenching.

Diagnosis of paramyotonia congenita is made upon evaluation of patient symptoms and case history. Myotonia must increase with exercise/movement and usually must worsen in cold temperatures. Patients that present with permanent weakness are normally not characterized as having PC. Electromyography may be used to distinguish between paramyotonia congenita and myotonia congenita [3,4]. Genomic sequencing of the SCN4A gene is the definitive diagnostic determinant.

Paramyotonia congenita (as well as hyperkalemic periodic paralysis and the potassium-aggravated myotonias) is caused by mutations in a sodium channel, SCN4A.. These

mutations affect fast inactivation of the encoded sodium channel. There are also indications that some mutations lead to altered activation and deactivation. The result of these alterations in channel kinetics is that there is pro

longed inward (depolarizing) current following muscle excitation. There is also the introduction of a “window current” due to changes in the voltage sensitivity of the channel’s kinetics. These lead to a general increase in cellular excitability

There has been one study of a large number of patients with paramyotonia congenita. Of 26 kindreds, it found that 17 (71%) had a mutation in SCN4A while 6 (29%) had no known mutation. There is no major difference between these two groups except that patients with no known mutation have attacks precipitated less by cold but more by hunger, are much more likely to have normal muscle biopsies, and show less decreased compound muscle action potentials when compared to patients with known mutations [5].

Some patients do not require treatment to manage the symptoms of paramyotonia congenita. Others, however require treatment for their muscle stiffness and often find mexiletine to be helpful. Others have found acetazolamide to be helpful as well. Avoidance of myotonia triggering events is also an effective method of myotonia prevention.

## References

1. Eulenburg, A.: Über eine familiäre durch 6 Generationen verfolgbare Form kongenitaler Paramyotonie. *Neurol. Zbl.* 5, 265–272 (1886); 12: 265-272
2. De Silva S, Kuncl R, Griffin J, Cornblath D, Chavoustie S. Paramyotonia congenita or hyperkalemic periodic paralysis? Clinical and electrophysiological

features of each entity in one family. *Muscle Nerve* 1990; 13 (1): 21-26.

3. Subramony S, Malhotra C, Mishra S . Distinguishing paramyotonia congenita and myotonia congenita by electromyography. *Muscle Nerve* 1983; 6 (5): 374-379.
4. Streib E. Evoked response testing in myotonic syndromes. *Muscle Nerve* 1984; 7 (7): 590-592
5. Millar T, Dias da Silva M, Miller H, Kwiecinski H. Correlating phenotype and genotype in the periodic paralyses. *Neurol.* 2004; 63 (9): 1647-1655
6. Benstead TJ, Camfield PR, King DB. "Treatment of paramyotonia congenita with acetazolamide" *Can J Neurol Sci* 1987; 14: 156-158.

**Correspondence:**

Rajesh K Kulkarni  
Department of Paediatrics  
B J Medical college and Sassoon Hospital  
Pune, Maharashtra  
India

Phone: 0091-9224799523, 0091-9209168561

e-mail docrajesh75@yahoo.com  
rajacoolkarni@yahoo.com

Fax: 0091-22 23735599